

Normal Dimensions of Lateral Femoral Condyle in Pakistani Population

Mohib Ullah Khan¹, Hidayat Ullah², Saeed Ahmad², Zia Ullah³, Mehtab Ullah⁴, Zahid Askar⁵, Malik Javed Iqbal⁵.

¹Orthopedic Surgeon Department, DHQ Hospital Miranshah, North Waziristan Tribal District, Pakistan, ²Orthopaedics Department, Peshawar Medical College, Peshawar, Pakistan, ³Orthopaedics, Khalifa Gul Nawaz Hospital, Bannu, Pakistan, ⁴Arthroscopy and Sports Surgery, Medical Teaching Institute, Hayatabad Medical Complex, Peshawar, Pakistan, ⁵Orthopedic Department, Peshawar General Hospital, Peshawar, Pakistan.

ABSTRACT

Background: The medial condyle is wider and having larger surface area for articulation than lateral femoral condyle however anteroposteriorly lateral femoral condyle is larger. The aim of this study was to find normal dimensions of lateral femoral condyle in Pakistani population.

Methods: This Cross-sectional descriptive study, carried out from September 2023 to May 2024 in Radiology department of Peshawar General Hospital, Peshawar with sample size of 385. Non probability convenience sampling technique was used. All healthy adult, intact femur with clear features were included and scanned through magnetic resonance imaging. Data analysis was done through SPSS version 22, descriptive analysis was done and association was assessed by applying independent sample t-test and ANOVA. P-value ≤ 0.5 was considered statistically significant.

Results: About 54% (n=149) male participants and 60% (n=67) of females had right knee measurements, whereas 46% (n=125) males and 40% (n=44) females had measurements of their left knee. There was no significant relationship between gender and the measured side (p=0.169). Age and size of the lateral femoral condyle were shown to be significantly correlated (p=0.027). Males exhibited greater femoral condyle dimensions, notch widths, and heights compared to females (p<0.001). Furthermore, ANOVA showed statistically significant variations in parameters of lateral femoral condyle, notch width, and height with age (p<0.001).

Conclusion: This study demonstrates that the femoral condyles parameters depend on several variables and differ by gender and region. Considering this study, accurate tunnel in lateral femoral condyle can be made for anterior cruciate ligament graft in ACL injury.

Keywords: Femoral Condyles, Lateral Femoral Condyle Dimensions, Magnetic Resonance Imaging.

Corresponding Author:

Dr. Mehtab Ullah

Fellow Arthroscopy and Sports Surgery,

Medical Teaching Institute, Hayatabad Medical Complex, Peshawar, Pakistan.

Email: Mehtabullah_bangash@hotmail.com

Doi: <https://doi.org/10.36283/ziun-pjmd13-4/019>

How to cite: Khan MU, Ullah H, Ahmad S, Ullah Z, Ullah M, Askar Z, Iqbal MJ, Khan G Normal Dimensions of Lateral Femoral Condyle in Pakistani Population. Pak J Med Dent. 2024;13(4): 148-155. Doi: <https://doi.org/10.36283/ziun-pjmd13-4/019>.

Received: Sat, Aug 17, 2024 **Accepted:** Tue, Oct 01, 2024 **Published:** Thu, Oct 24, 2024

INTRODUCTION

The largest, intricate, and most dislocated joint in the whole human body is the knee joint. Knee mechanics are greatly affected by the intricate multidimensional 3-D configuration of the distal lateral and medial femoral condyles¹. The knee is vulnerable to intense forces, long-term conditions, and collisions since it is in between the two bones, that is femur and tibia which carries the whole weight of the upper body². Although males are more involved in sports activity and strenuous physical work the incidence of injuries and chronic diseases to the knee joint is higher in females than the male³. Men's and women's knees are anatomically different from each other reported by several studies^{4,5}. Some studies reported that the anterior femoral condyle height in males is slightly higher than that of females which results in the formation of knee implants having thinner and narrower anterior flange for females⁶.

The distal end of the femur is formed by two condyles that articulate with the tibial bone to form a knee joint; they are covered by articular cartilage⁷⁻⁹. The medial condyle is wider and has a larger surface area for articulation than the lateral femoral condyle however, Antero-posteriorly lateral femoral condyle is larger. They are cam-shaped when imaged from the lateral view¹⁰. These condyles meet at the anterior surface but are separated from each other posteriorly by a deep fossa called intercondylar fossa and extend past the popliteal surface plane¹¹. The medial surface of the LFC and MFC forms the lateral and medial wall of the fossa respectively. One can plainly palpate the bulge and prominent convex medial aspect of the medial condyle^{12,13}. Differences in ethnicity, age, sex, habits, ways of life, environmental conditions, and diet, affect anthropometric measurements of the femur, which vary from place to place. The fields of forensic

healthcare, archaeological research, prosthetics, sports surgery, and biomedical engineering can all benefit greatly from these measurements. Numerous radiologic research studies have been carried out to measure different parameters of distal femoral condyles in humans^{14,15}. The most accurate method for assessing femoral condyles is magnetic resonance imaging¹⁶. To make a tunnel in the lateral femoral condyle in anterior cruciate ligament injury, the current study aim was to find the width/ dimensions of the lateral femoral condyle so that the length of the femoral tunnel is determined.

METHODS

This was a cross-sectional descriptive study that lasted for 9 months, starting in September 2023 and ending on May 30th, at Radiology department, Peshawar General Hospital, Peshawar. Non-probability convenient sampling technique was used. The sample size was initially calculated to be 211 through OpenEpi, based on a population of 2,481,000 from Peshawar, with a confidence level of 95%, a margin of error of 3%, and an anticipated frequency of ACL injuries in male about 5.2%.¹⁷ However, to ensure greater accuracy and reliability of the results, a total of 385 participants were included in the study. All healthy and intact femur with clear features adults were included in the study whereas patients with fractured bones, congenital bone/joint disorders, and incomplete bones were excluded from the study.

Consent form from participants was taken and ethical approval was also taken from the ethical committee (Ref No. 1010, on dated 15/08/2023). Anthropometric data was recorded on the questionnaire after completion of scan and measuring the various parameters on radiographic images.

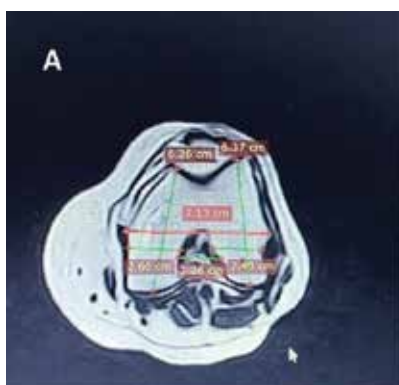


Figure 1: Anteroposterior dimension of Medical and Lateral femoral condyle (6.37cm and 6.26cm respectively), intercondylar distance (7.13cm), and Femoral Notch width (2.26cm)

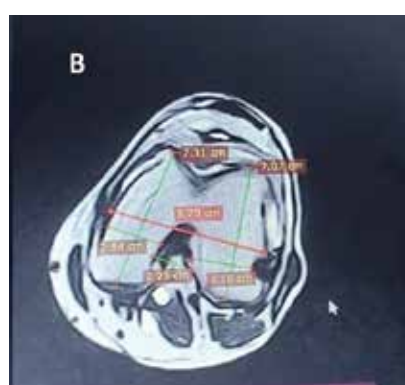


Figure 2: Anteroposterior dimension of Medical and Lateral femoral condyle (7.07cm and 7.31cm respectively), intercondylar width (8.25cm), and Femoral Notch width (2.23cm)

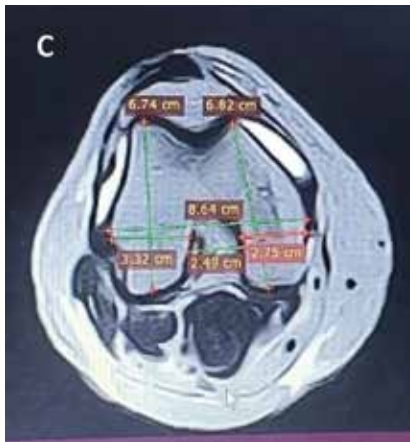


Figure 3: Anteroposterior dimension of Medical and Lateral femoral condyle (6.74cm and 6.22cm respectively), intercondylar distance (8.64cm), and Femoral Notch width (2.49cm)

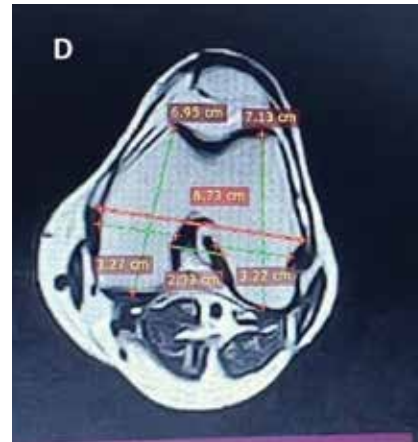


Figure 4: Anteroposterior dimension of Medical and Lateral femoral condyle (7.13cm and 6.95cm respectively), intercondylar width (8.73cm), and Femoral Notch width (2.33cm)

A 1.3T magnetic resonance imaging (MRI) machine was quality assured prior this study. All the subjects were scanned through MRI with knee joint protocol. During scanning the foot of the individual was placed in special footgear in order to avoid mobility of the limb and standardize the position for lower limb procedure. There was no contrast media administration in this scanning procedure. T1 weighted, T2 weighted and proton density images were taken in axial, coronal and sagittal planes with thin slices and slice gap. Additional reconstruction from raw data in 3-D plane was also performed. The antero-posterior (AP) measurements of the femoral condyles, medial condyle dimensions, lateral condyle dimensions, trans-epicondylar axis, notch width and notch height were measured through caliper and measurement tool.

Data analysis was done through SPSS version 22, descriptive statistical analysis and independent sample t-test for association lateral femoral condyle, width and height of notch with gender of the participants. Chi-square test was used to assess relation of the side of knee with gender and different age groups. Bivariate analysis for the correlation of differ-

ent parameters of the participants such as age, dimension of lateral femoral condyle, width and height of the notch. All results were summarized in tabular and graphical form. Moreover, independent t-tests and ANOVA were used to find out the differences among groups. P-value ≤ 0.5 was considered statistically significant.

RESULTS

Within the male participants, the data indicates that 149 (54.3%) individuals had measures taken on their right knee joint, whereas 125 (45.7%) individuals had measurements done on their left knee joint. Among the female participants, 67 (60.3%) included measures of their right knee, whereas 44 (39.7%) included measurements of their left knee. The obtained p-value of 0.169 indicates no significant correlation between gender and the side of the knee joint. The age group distribution exhibits a mostly uniform spread, with a little decline in the participation count among older age groups. No significant correlation between age and the presence of the right or left knee joint in this cohort ($p=0.973$) (Table 1).

Table 1: Association of Gender and Age with The Side of The Knee Joint

Variable	Detail	Side of Knee Joint		P value
		Right	Left	
Gender	Male	149 (54.3%)	125 (45.7%)	0.169
	Female	67 (60.3%)	44 (39.7%)	

Age of the participants	20-25 Years	6 (54.5%)	5 (45.5%)	0.973
	26-30 Years	67 (58.7%)	47 (41.3%)	
	31-35 Years	59 (57.2%)	44 (42.8%)	
	36-40 Years	39 (54%)	32 (46%)	
	41-45 Years	30 (53.5%)	26 (46.5%)	
	46-50 Years	13 (52%)	12 (48%)	
	> 50 Years	2 (40%)	3 (60%)	

Cross-tabulation and Chi-square test

The highest number of participants were noted in age group 26-30 years while least in age group >50 years. The mean value of dimension of lateral femoral condyle in age group 20-25 was 2.87cm with standard deviation of 0.29cm, mean value in age group 26-30 was 3.15 ± 0.36cm, mean value in age group 31-35 was 2.90 ± 0.18cm, in age group 36-40 was 2.80 ± 0.26cm, in age group 41-45 was 2.99 ± 0.24cm, in age group 46-50 was 3.37 ± 0.05cm while in age group >50 was 3.35 ± 0.008cm noted (Table 2).

Table 2: Dimension of Lateral Femoral Condyle with Age Groups.

Age of the Subject	N	Minimum	Maximum	Mean±SD
20-25 Years	11	2.57	3.23	2.87±0.29
26-30 Years	114	2.28	3.54	3.16±0.36
31-35 Years	103	2.60	3.17	2.90±0.18
36-40 Years	71	2.46	3.20	2.80±0.26
41-45 Years	56	2.54	3.23	2.99±0.24
46-50 Years	25	3.10	3.40	3.37±0.06
>50 Years	5	3.35	3.37	3.35±0.01
Total	385	2.28	3.54	3.01±0.31

A statistically significant association (p-value of 0.027) between the participant's age and the dimension of the lateral femoral condyle. Nevertheless, the relationship between age and other factors, such as the breadth and height of the notch, lacks statistical significance, as shown by p-values of 0.150 and 0.265, respectively. A statistically significant negative correlation ($r=-0.272$, $p=0.0001$) exists between the lateral femoral condyle's dimension and the notch's height. No significant link between the width of the notch and the side of the knee joint, as shown by p-values of 0.493 and 0.928, respectively. Notably, there is a significant positive relationship between the width and height of the notch ($r=0.544$, $p=0.0001$), indicating that as the breadth of the notch grows, its height also rises. Furthermore, the association between the width of the notch and the side of the knee joint is also statistically significant ($r=0.105$, $p=0.039$), while the intensity of the link is somewhat weak. No statistically significant relationship between the side of the knee joint and the height of the notch ($p=0.568$) (Table 3).

Table 3: Bivariate Analysis for the Correlation of Different Parameters of the Participants.

Parameters	Age of the subject	Dimension of lateral Femoral condyle	Width of Notch	Height of Notch
Age of the subject	1	r = 0.603 P-value= 0.027	r = 0.150 P-value= 0.003	r = 0.265 P-value <0.001
Dimension of lateral femoral condyle		1	r = -0.035 P-value= 0.493	r = -0.272 P-value <0.001
Width of Notch			1	r = 0.544 P-value <0.001
Height of Notch				1

Pearson correlation

The mean value for the dimension of the lateral femoral condyle among male participants was 3.0586±0.31 cm. By contrast, the female participants had a much lower average value of 2.8932±0.27 cm. These findings indicate that males generally have a greater horizontal dimension of the lateral femoral condyle than females (p-value <0.001). A comparison of notch width revealed that men had an average width of 2.3482, with a standard deviation of 0.35905. In contrast, girls had an average width of 2.1714, with a standard deviation of 0.27218. The measurements suggest that males often have a broader notch than females (p-value <0.001). Concerning the notch height, the average height of male participants was 2.6656, with a standard deviation of 0.39302. The mean height of female participants was somewhat lower at 2.5566, with a standard deviation of 0.25733. These results indicate that men generally have a higher notch height than females having p-value = 0.002 (Table 4).

Table 4: Comparison of Gender with Dimension of lateral femoral condyle, Width and Height of Notch

Variable	Gender	N	Mean ± SD	P-value
Dimension of the lateral femoral condyle (cm)	Male	274	3.0586±0.31	<0.001
	Female	111	2.8932±0.27	
Width of notch (cm)	Male	274	2.3482±0.35	<0.001
	Female	111	2.1714±0.27	
Height of notch (cm)	Male	274	2.6656±0.39	0.002
	Female	111	2.5566±0.25	

Independent Sample T-test

The independent t-test was used to assess the difference in dimension of lateral femoral condyle, width and height of notch between the right and left sides of the knee joint. For the dimension of the lateral femoral condyle, the right side had a mean of 3.0044 cm and a standard deviation of 0.31891, while the left side had a mean of 3.0191 cm, and a standard deviation of 0.31413 with a p=0.651, indicating no significant difference between both sides. Regarding the width of the

notch, the right side had a mean of 2.2677 (SD = 0.33693), compared to the left side, which had a mean of 2.3246 (SD = 0.35651). For the height of the notch, the right side showed a mean of 2.6238 (SD = 0.36048), while the left side had a mean of 2.6270 (SD = 0.36157), for the width of the notch, the p-value was 0.109, which also suggests no significant difference; and for the height of the notch, the p-value was 0.932, indicating a lack of significant difference between the two sides (Table 5).

Table 5: Comparison of Side with Dimension of lateral femoral condyle, Width and Height of Notch

Variable	Side	N	Mean ± SD	P-value
Dimension of the lateral femoral condyle (cm)	Right	212	3.0044cm±0.318	0.651
	Left	173	3.0191cm±0.314	
Width of notch (cm)	Right	212	2.2677cm±0.336	0.109
	Left	173	2.3246cm±0.356	
Height of notch (cm)	Right	212	2.6238cm±0.360	0.932
	Left	173	2.6270cm±0.361	

Independent Sample T-test

DISCUSSION

The distal femur's dimensions and form play a significant role when determining the knee mechanics. Distal femur characteristics have a significant impact on a number of diseases, including OA and patellofemoral pathologies¹⁸. Racial, gender, and regional differences exist in the distal femur's dimensions¹⁹. The mean lateral femoral condyle dimension in this study for males is 3.05 ± 0.31 cm, while for females it is 2.89 ± 0.27 cm. These values are comparable to data from a study conducted in Turkey, with a mean value of 2.44 ± 2.58 cm, and another study in Ohio, reporting a mean value of 2.42 ± 3 cm.¹⁸⁻²⁰ The average lateral condyle thickness measured was 2.53 ± 3.15 cm, which was slightly greater than the values reported for Caucasian individuals, with 2.36 ± 2.18 cm and 2.48 ± 3 cm from studies conducted in Turkey and Ohio, respectively^{19,18}.

The mean notch width in this study is 2.29 ± 0.34 cm, which is slightly higher than the 2.05 ± 2.2 cm reported in a study from Greece, but lower than the mean value found in Kenya^{21,22}. The mean notch height in our study is 2.63 ± 0.36 cm, which is slightly higher than the values reported in Greece and Turkey, as indicated by previous studies^{23,24}.

The limitation of this study is that we assessed only a few parameters of the lateral femoral condyle such as lateral femoral condyle dimension, notch height, and notch width. We recommend orthopedic surgeons, implants, and prosthesis designers take help from the data of this study for designing accurate implants and prostheses for the Pakistani popu-

lation, as there is an association between lateral condyle dimension and gender.

CONCLUSION

This study demonstrates that the femoral condyles parameters depend on several variables and differ by gender and region. Considering this study, an accurate tunnel in the lateral femoral condyle can be made for anterior cruciate ligament graft in ACL injury. Sports health professionals and orthopedic surgeons should take this into account when planning implants and performing procedures. Accurate and appropriate size implants will reduce the risk of implant loosening and the patient will feel comfortable. Forensic specialists in common practice will also benefit from the data collected here.

DECLARATIONS

This study was conducted to analyze and compare anatomical dimensions of the lateral femoral condyle and notch width in the study population, highlighting differences across gender and comparing the results with previous studies conducted in different regions.

ACKNOWLEDGMENTS

We would like to acknowledge all patient's contribution in this study.

CONFLICT OF INTEREST

The authors have no conflict of interest.

ETHICAL APPROVAL

The permission was obtained from the Institutional

Review Board/Ethics Committee of the Peshawar General Hospital, Peshawar, with ethical approval reference no. 1010, on dated 15/08/2023.

FUNDING

This research received no external funding.

PATIENT CONSENT

Written informed consent was obtained from all participants prior to the study.

AUTHORS CONTRIBUTION

MUK & HU: Designed and conceived the idea, registered the trial and helped with data collection and manuscript writing. SA, GK, & ZU: Manuscript editing, statistical analysis. MU & ZA: Data collection, data interpretation. HU & GK: Did statistical analysis, final review, and manuscript editing. MJI & ZA: Supervised the entire study and was responsible for its integrity.

REFERENCES

1. Lin J, Zhang S, Xin E, Liang M, Yang L, Chen J. Anterior cruciate ligament femoral footprint is oblong-ovate, triangular, or two-tears shaped in healthy young adults: three-dimensional MRI analysis. *Knee Surgery, Sports Traumatology, Arthroscopy*. 2023 Dec;31(12):5514-23. <https://doi.org/10.1007/s00167-023-07606-6>
2. Grothues SA, Radermacher K. Variation of the three-dimensional femoral J-curve in the native knee. *Journal of Personalized Medicine*. 2021 Jun 23;11(7):592. <https://doi.org/10.3390/jpm11070592>
3. Kakouris N, Yener N, Fong DT. A systematic review of running-related musculoskeletal injuries in runners. *Journal of sport and health science*. 2021 Sep 1;10(5):513-22. <https://doi.org/10.1016/j.jshs.2021.04.001>
4. Keibach M, Mick E, Kirschner S, Luetzner J, Bader R. Intraoperative analysis of patellofemoral joint morphology before and after total knee arthroplasty. <https://doi.org/10.1007/s00132-022-04224-x>
5. Hsu CP, Lee PY, Wei HW, Lin SC, Lu YC, Lin JC, Huang CH. Gender differences in femoral trochlea morphology. *Knee Surgery, Sports Traumatology, Arthroscopy*. 2021 Feb;29:563-72. <https://doi.org/10.1007/s00167-020-05944-3>
6. Conley S, Rosenberg A. The Female Knee : 2007;15:31–6. DOI: 10.5435/00124635-200700001-00009
7. Li Z, Liu G, Tian R, Kong N, Li Y, Li Y, Wang K, Yang P. The patellofemoral morphology and the normal predicted value of tibial tuberosity-trochlear groove distance in the Chinese population. *BMC Musculoskeletal Disorders*. 2021 Dec;22:1-3. <https://doi.org/10.1186/s12891-021-04454-8>
8. Lingamdenne PE, Marapaka P. Examination evaluation and statistical analysis of human femoral anthropometry in Hyderabad and Secunderabad regions, India. *Indian J Clin Anat Physiol*.

- 2016;3(4):427. DOI: 10.5958/2394-2126.2016.00097.9
9. Gray's Anatomy: The Anatomical Basis of Clinical Practice 42nd Edition– Classic Medical Books. <https://www.classicmedicalbooks.pk/products/grays-anatomy-the-anatomical-basis-of-clinical-practice-42nd-edition>. Accessed: 2024-08-29
10. Qu S. Research and Analysis of Knee Joint Prosthesis Design Based on 3D Simulation Technology Based on Computer Method. In Proceedings of the 2022 7th International Conference on Systems, Control and Communications 2022 Oct 14 (pp. 29-36). <https://doi.org/10.1145/3575828.357583>
11. Jadawala V, Deshpande S, Taywade S, Wamborikar H, Pisulkar G, Salwan A. A Review on Morphometry of the proximal femur and its clinical significance. *Journal of Pharmaceutical Negative Results*. 2022 Dec 30:2855-63. DOI: <https://doi.org/10.47750/pnr.2022.13.S09.349>
12. Agarwal N, To K, McDonnell S, Khan W. Clinical and radiological outcomes in robotic-assisted total knee arthroplasty: a systematic review and meta-analysis. *The Journal of arthroplasty*. 2020 Nov 1;35(11):3393-409. <https://doi.org/10.1016/j.arth.2020.03.005>
13. Urabe K, Mahoney OM, Mabuchi K, Itoman M. Morphologic differences of the distal femur between Caucasian and Japanese women. Vol. 16, *Journal of orthopaedic surgery (Hong Kong)*. 2008. p. 312–5. <https://doi.org/10.1177/230949900801600309>
14. Prasad V, Jagdish P. Study of the Correlation of Bicondylar and Intercondylar Width with the Length of Femur in Uttarakhand Population. 2018;17(6):68–9. DOI: 10.9790/0853-1706096869
15. Chandran M. Reconstruction of femur length from its fragments in South Indian males - *Journal of Forensic and Legal Medicine*. <https://doi.org/10.1016/j.jflm.2011.12.010>
16. Atturo F, Portanova G, Russo FY, Seta DD, Mariani L, Borel S, Greco A, Mosnier I, Mancini P. Cochlear implant in immune mediated inner ear diseases: Impedance variations and clinical outcomes. *Cochlear Implants International*. 2022 Mar 4;23(2):70-9. <https://doi.org/10.1080/14670100.2021.1992149>
17. Rigg JD, Panagodage Perera NK, Toohey LA, Cooke J, Hughes D. Anterior cruciate ligament injury occurrence, return to sport and subsequent injury in the Australian High Performance Sports System: A 5-year retrospective analysis. *Physical Therapy in Sport*. 2023 Nov 1;64:140–6.
18. Ahmad N, Ghafoor A, Iqbal W, Shaukat M, Khalid A, Ahmad I. An Anatomical Study of Proximal End of Femur in Human Cadavers from a Single Center in Pakistan. 2021;7(01):17–20.
19. Wang G, Liu M, Zhang Z, Liu S, Zhang G, Yang C. A simplified relationship between the femoral trochlea and the femoral condyle: A sagittal MRI analysis by an ellipse-fitting approach. *Clinical Anatomy*.

2020 May;33(4):500-6. <https://doi.org/10.1002/ca.23395>

20. Everhart JS, Chaudhari AMW, Flanigan DC. Creation of a simple distal femur morphology classification system. *J Orthop Res*. 2016;34(6):924–31. <https://doi.org/10.1002/jor.23102>

21. Yazar F, Imre N, Battal B, Bilgic S, Tayfun C. Is there any relation between distal parameters of the femur and its height and width? *Surg Radiol Anat*. 2012;34(2):125–32. <https://doi.org/10.1007/s00276-011-0847-1>

22. Liu HC. Review of gross anatomy of the Chinese knee. Vol. 83, *Taiwan yi xue hui za zhi*. Journal of the Formosan Medical Association. 1984. p. 317–25. PMID: 6588143.

23. Lakati KC, Ndeleva BM, Kibet CK, Student M, Odhiambo SM, Student M, et al. Figure 1 Measurement of AP diameter lateral condyle Figure 2 Measurement of M-L width RESULTS. :67–72.

24. Terzidis I, Totlis T, Papathanasiou E, Sideridis A, Vlasik K, Natsis K. Gender and Side-to-Side Differences of Femoral Condyles Morphology: Osteometric Data from 360 Caucasian Dried Femora. *Anat Res Int*. 2012;2012(1):1–6. <https://doi.org/10.1155/2012/679658>

24. Khanal L, Shah S, Koirala S. Estimation of total length of femur from its proximal and distal segmental measurements of disarticulated femur bones of nepalese population using regression equation method. *J Clin Diagnostic Res*. 2017;11(3):HC01–5. doi: 10.7860/JCDR/2017/23694.9471

25. Hussain F, Abdul Kadir MR, Zulkifly AH, Sa'At A, Aziz AA, Hossain MG, et al. Anthropometric measurements of the human distal femur: A study of the adult malay population. *Biomed Res Int*. 2013;2013. <https://doi.org/10.1155/2013/175056>

