

Evaluating Vitamin E's Antioxidative Effect on Carbamazepine-Induced Spleen Damage in Rat Models

Asma Basharat Ali¹, Nadia Younus¹, Sahrish Mukhtar¹, Lubna Faisal², Tayyaba Kazmi³, Alina Atif⁴

¹Department of Anatomy, Jinnah Medical and Dental College, Sohail University, ² Department of Anatomy, Liaquat National Hospital and Medical College, ³ Department of Anatomy, Baqai Medical College, Baqai Medical University,

⁴ Department of Physiology, Jinnah Medical and Dental College, Sohail University, Karachi

ABSTRACT

Background: The spleen is essential for the body's homeostasis and immune system. Carbamazepine (CBZ) is known to cause toxicity to several organs, including the spleen, through oxidative stress. While, vitamin E (Vit E) is a proven antioxidant against toxins. Thus, this study evaluated the antioxidative effect of Vit E on hematological and splenic toxic changes, caused by carbamazepine in rats.

Methods: This in-vivo preclinical experimental study was conducted from March-June 2020, at Jinnah Medical and Dental College, Karachi. Forty adult male rats, weighing 150-200 grams were included and randomly divided into 4 groups. Group I was control; Group II received oral Carbamazepine (50mg/kg/day), Group III received Carbamazepine (50mg/kg/day) with Vit E (200mg/kg/day), and Group IV received Vit E (200mg/kg/day) daily. After 6 weeks, animals were sacrificed, blood samples were drawn and splenic tissue was processed for morphological examination. SPSS version 22 was used, and ANOVA was applied to investigate the difference of means with $p \leq 0.05$ considered significant.

Results: Our findings showed that Group II rats had significantly decreased final body weights, and absolute and relative spleen weights compared to control. Lower hemoglobin, lymphocytes, and platelets, and significantly increased TLC and neutrophils were observed in Group II compared to control and Group IV. Histology showed a thickened capsule, reduced white pulp, and congested red pulp in Group II spleens whereas these toxic effects were reduced in Group III.

Conclusion: Our study demonstrated that the hematologic and splenic toxic effects of carbamazepine were lessened significantly with the antioxidative properties of vitamin E.

Keywords: Carbamazepine, Vitamin E, Spleen, Oxidative Stress, Hematology.

Corresponding Author:

Nadia Younus

Anatomy Department,
Jinnah Medical and Dental College, Sohail University,
Karachi, Pakistan.

Email: nad_younus@hotmail.com

ORCID ID: 0000-0001-9994-9547

Doi: 10.36283/PJMD13-3/018

How to cite: Ali A B, Younus N, Mukhtar S, Faisal L, Kazmi T, Atif A, Evaluating Vitamin E's Antioxidative Effect on Carbamazepine-Induced Spleen Damage in Rat Models. Pak J Med Dent. 2024;13(3): 132-139. Doi: 10.36283/PJMD13-3/018

Received: Tue, May 21, 2024 **Accepted:** Sat, June 08, 2024 **Published:** Wed, 24 July 2024

This is an open-access article distributed under the terms of the Creative Commons Attribution License (CC BY) 4.0
<https://creativecommons.org/licenses/by/4.0/>

INTRODUCTION

The spleen is the largest lymphoid organ which plays a crucial role in both the body's homeostasis and immune system. The histological structure of splenic parenchyma consists of red pulp and white pulp. Red pulp contains cords of billroth and sinusoids while white pulp consists of lymphocytes around the central artery. The marginal zone is present at the interphase of red and white pulp¹. Abnormal red blood cells are removed from the splenic circulation (culling) and other red blood cells lose their abnormal intracellular rigid inclusions (pitting) by the macrophages attached to the cords of billroth². On the other hand, the spleen mediates the innate immune response to circulating pathogens through prompt production of antibodies by the B cells of the marginal zone and adaptive immune response through delayed production of specific antibodies by the follicular B cells³. These multifaceted functions of the spleen are essential for the body's optimal performance, and any compromise to its functional and structural integrity secondary to oxidative stress represents a significant health risk⁴. Oxidative stress results from the difference between the reactive oxygen species (ROS) and free radicals and the inbuilt antioxidant protection mechanisms. These ROS and free radicals damage cells and tissues⁵.

CBZ is known to cause toxicity to several organs, including the spleen, through oxidative stress by its active metabolite, carbamazepine-10,11-epoxide. Carbamazepine-10,11-epoxide is formed as a result of CBZ metabolism in the liver. It overwhelms the antioxidant systems of the cell including the cell membrane, resulting in increased permeability and cellular damage^{6,7}. Even with the advent of newer and safer anti-epileptic drugs, carbamazepine remains one of the most prescribed drugs for epilepsy, owing to its great balance between affordability, accessibility, and effectiveness⁸. Besides being used for the treatment of grand mal and psychomotor epilepsy, CBZ is the first-line drug for neuropathic pain like trigeminal neuralgia. It also acts as a second-line or a combination drug for bipolar mood disorder, schizophrenia, attention deficit hyperactivity, and post-traumatic stress disorders⁹.

Vitamin E (Vit E), a lipophilic antioxidant, has proven to alleviate oxidative challenges elicited by environmental toxins. α -tocopherol is the chief natural form of Vit E. It carries out most of the antioxidant and biological activities and is the most beneficial form for humans. It protects polyunsaturated fatty acids present in cellular membranes and lipoproteins from lipid peroxidation by breaking the chain reaction^{10,11}.

The present preclinical experimental study was designed given the limited data available on the toxic effects of CBZ on the histological architecture of the spleen and its hematological correlation. Thus, we evaluated the protective potential of a natural antioxi-

dant, Vit E, against these changes to explore its future prophylactic use.

METHODS

This was an *in vivo* preclinical experimental study, conducted from March 2020 to June 2020, in the Anatomy Department of Jinnah Medical and Dental College, Karachi, after getting ethical approval from the Ethics Review Committee of Sohail University, vide protocol no: 000028/20. 40 male Sprague Dawley albino rats, 10-12 weeks in age and 150-200 grams in weight were included in this study. Female rats and rats falling sick were excluded from the study. Animals were obtained and housed in plastic cages in the Animal House. They were retained in a monitored environment of a 14/10 hours of light/night cycle, and a maintained temperature of 25°C. Animals were acclimatized for 10 days before the experiment, were provided with free access to water and a standard rat diet, and were taken care of according to the ethical standards of Pakistan.

The animals were randomly and equally divided into 4 groups (Groups I, II, III, and IV). The rats of Group I, the control group, were kept away from any intervention. Group II animals were given a once-daily dose of 50mg/kg of CBZ after fasting overnight. Group III animals were also given the same once-daily dose of CBZ with Vit E in the dose of 200mg/kg/day after an hour of taking CBZ. While Group IV animals received only Vit E in a dose of 200mg/kg/day. The drugs were administered in liquid form by gastric gavage. The rats were weighed using an electronic weighing scale at the start of the experiment and then subsequently weighed at a regular interval of 2 weeks up until the experiment ended.

At the end of the study period of 6 weeks, the rats were weighed for the final time and then sacrificed after being anesthetized with chloroform. The animals were dissected by a midline incision and the thoracic and abdominal cavities were exposed. Blood was collected through cardiac puncture. A complete blood count was performed on blood samples through the Hematology Analyzer (model: Sysmex kx-21). Spleens were harvested and weighed. The absolute organ weight was recorded, and the relative organ weight was calculated by using the formula: Relative organ weight = (absolute organ weight/final body weight) \times 100. The splenic tissue was processed and stained with hematoxylin and eosin so that the microscopic architecture of the spleen could be studied under a light microscope.

Data were analyzed using SPSS (Statistical Package for Social Sciences) version 23. The quantitative variables were described as mean values \pm standard deviation (Mean \pm SD). ANOVA with post hoc Tukey's test was applied to measure significant differences within groups. P value \leq 0.05 was considered statistically

significant at a 95% confidence interval.

RESULTS

A total of forty rats were selected for the study and equally divided into 4 groups. The animals were assessed at the end of 6 weeks. General physical examination of animals showed that Control group I rats were energetic, healthy, and well-reactive to outer stimuli. CBZ-treated Group II rats, on the other hand, were inactive, weak, and ill. Vit E-protected Group III rats were active and alert but not as control. Group IV rats were as energetic, and responsive as control.

Table 1 shows that the Final weights of all the rats across all the groups were increased from their initial weights. There was a significant decrease in CBZ-treated Group II rats' final weight as compared to control Group I rats while the Vit E-treated group IV rats' final weight showed significant improvement in comparison to the mean final body weights of CBZ-treated Group II. There was an improvement in the rats' final weights when Vit E was co-administered in Group III rats though insignificant. (Table 1 & 2)

Table 1: Descriptive statistics of body and splenic weights among different groups.

Parameters	I	II	III	IV
	Control	CBZ	CBZ + Vit E	Vit E
	Mean ± SD			
Initial body weight (gm)	175.73 ± 4.82	177.65 ± 6.55	175.48 ± 6.86	176.57 ± 4.85
Final body weight (gm)	193.83 ± 9.30	182.79 ± 9.18	188.80 ± 8.89	191.51 ± 2.50
Absolute Spleen Weight (gm)	0.72 ± 0.13	0.42 ± 0.08	0.60 ± 0.05	0.66 ± 0.04
Relative Spleen Weight (gm)	0.37 ± 0.06	0.23 ± 0.05	0.32 ± 0.04	0.34 ± 0.02

The absolute and relative splenic weights of Group II showed a significant reduction in comparison to the control. Comparison between Group II to Group III showed significant betterment in the splenic weight

loss. There was also a significant rise in absolute and relative splenic weights of Vit E-treated Group IV when compared with CBZ-treated Group II. (Table 1 & 2)

Table 2: Comparative analytical statistics of body and splenic weights and hematological parameters among different groups.

Parameters	I vs II	I vs III	I vs IV	II vs III	II vs IV	III vs IV
	Control vs CBZ	Control vs CBZ + Vit E	Control vs Vit E	CBZ vs CBZ + Vit E	CBZ vs Vit E	CBZ + Vit E vs Vit E
Final body weight (gm)	0.008*	0.423	0.893	0.270	0.050*	0.839
Absolute Spleen Weight (gm)	<0.001*	0.010*	0.284	<0.001*	<0.001*	0.440
Relative Spleen Weight (gm)	<0.001*	0.052	0.457	<0.001*	<0.001*	0.650
Hemoglobin (g/dl)	0.416	0.985	0.917	0.241	0.801	0.753
Hematocrit (%)	0.090	0.021*	0.187	0.953	0.993	0.859

Total Leucocyte count (cells/ μ L)	0.044*	<0.160	0.999	0.933	0.057	0.198
Neutrophil count (%)	<0.001*	0.001*	0.342	<0.001*	<0.001*	0.069
Lymphocyte count (%)	<0.001*	0.032*	0.838	0.164	0.001*	0.191
Platelet count $\times 10^9$ /L	<0.001*	0.014*	0.908	0.225	<0.001*	0.071

Comparative analysis between groups was performed by ANOVA with post hoc Tukey's test. Significantly different when $p \leq 0.05$

CBZ administration in Group II decreased hemoglobin levels in comparison to Group I and the addition of Vit E in Group III improved the hemoglobin levels in comparison to CBZ-treated Group II, all these observations were statistically insignificant. The observed white blood cells in the CBZ-treated Group II were significantly affected in contrast to control Group I. The total leucocyte counts and percentage of neutrophils were

significantly higher and the percentage of lymphocytes was significantly lower in Group II. The co-administration of Vit E with CBZ did decrease the total leucocyte count but insignificantly. The platelet count decreased significantly in the CBZ-treated Group II and it improved with the concurrent administration of Vit E. The platelet count in the Vit E Group IV was near normal. (Table 2 & 3)

Table 3: Hematological parameters among different groups.

Parameters	I Control	II CBZ	III CBZ + Vit E	IV Vit E
	Mean \pm SD			
Hemoglobin (g/dl)	13.18 \pm 0.49	12.74 \pm 0.665	13.28 \pm 0.754	13.00 \pm 0.831
Hematocrit (%)	38.41 \pm 2.82	43.22 \pm 6.74	44.30 \pm 4.64	42.62 \pm 2.87
Total Leucocyte count (cells/ μ L)	4.10 \pm 0.55	5.10 \pm 1.31	4.88 \pm 0.56	4.15 \pm 0.91
Neutrophil count (%)	15.75 \pm 2.26	27.17 \pm 2.12	20.75 \pm 4.22	17.75 \pm 2.49
Lymphocyte count (%)	80.58 \pm 2.77	70.41 \pm 3.05	74.75 \pm 8.44	78.92 \pm 3.50
Platelet count $\times 10^9$ /L	593.08 \pm 43.12	432.25 \pm 97.71	493.17 \pm 65.72	572.08 \pm 88.57

Morphological analysis of splenic tissue through H and E-stained histological slides. 40X-magnified splenic sections of Control Group I rats revealed stroma made up of dense connective tissue capsule. The parenchyma consists of red pulp (RP) and white pulp (WP) containing lymphocytes (Fig.1A). The CBZ-treated Group II showed a thickened capsule, edematous parenchyma, and reduced white pulp with a poorly discernable marginal zone; the red pulp appears

congested (Fig.1B). In CBZ & Vit E (Group III) splenic tissue showed increased white pulp, with considerably increased thickness of a less-discernable marginal zone with a generalized increased area of PALS. The red pulp appears less congested (Fig. 1C). The Group IV (Vit E) tissue showed splenic architecture similar to the control tissue, with a thicker marginal zone (Fig. 1D).

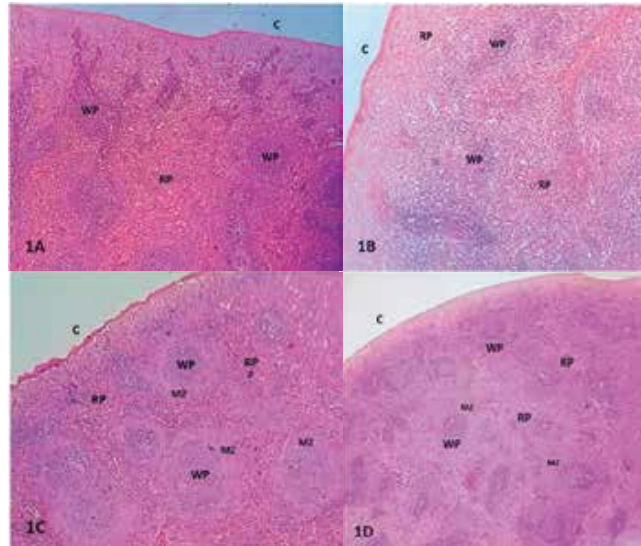


Figure 1: Photomicrographs of rat spleen at 40X. 1A shows normal architecture with red pulp (RP) and white pulp (WP) consisting of peri arteriolar lymphoid sheath (PALS) and marginal zone (MZ) in Group I. 1B showing thickened capsule (C), reduced WP including PALS and marginal zone and congested RP in Group II. 1C showing a less thickened capsule (C), less congested RP and increased WP and MZ in Group III. 1D showing the normal architecture of the spleen in Group IV.

At a higher magnification of 100X H & E-stained slide of CBZ + Vit E protected group III spleen shows the parenchyma consisting of the red pulp (RP) and white pulp (WP). The red pulp consists of reticular tissue and less congested sinusoids, while the white pulp (WP) consists of increased lymphocytes as either lymphoid nodules or arranged around the central artery as periarteriolar

lymphoid sheath or PALS with distinctly increased marginal zones (MZ) in-between red and white pulp. (Fig. 2A). At 400X magnification the CBZ-treated Group II showed vacuolization in the tunica media of the central artery, around which reduced PALS is present (Fig. 2B)

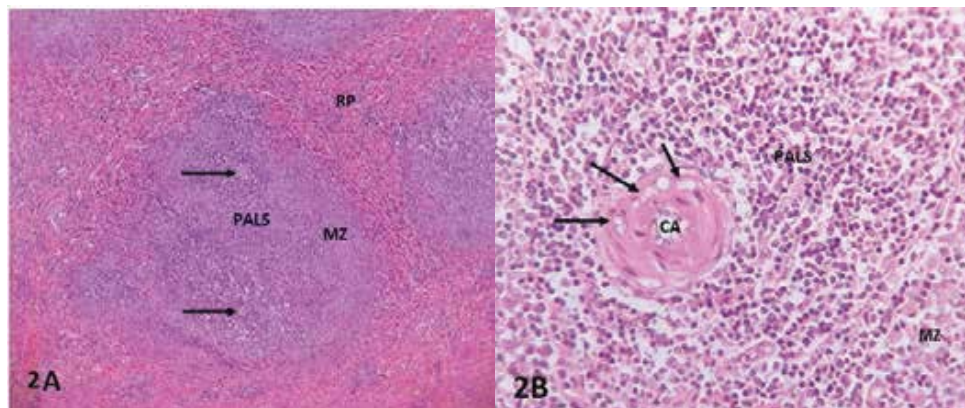


Figure 2A: Photomicrographs of rat spleen at 100X showing slightly increased PALS and markedly increased MZ at the interphase of RP and WP in Group III. 2B: Group II rat spleen at 400X showing vacuolization (arrows) in tunica media of central artery (CA).

DISCUSSION

Although carbamazepine has been observed to cause a decrease in humoral and cellular immune responses, while other studies point towards the immunomodulating properties of the drug, very few studies have seen the oxidative effect of carbamazepine on

the lymphoid organ, the spleen^{12,13}. The present study observed the changes in the histology of the spleen and hematology, secondary to carbamazepine administration and its amelioration by a potent antioxidant, Vit E.

In this experiment, the effect on body and spleen weights were compared across the groups. The mean body weight of Group II carbamazepine-treated animals decreased significantly as compared to control Group I. This is similar to the studies of Osuntoken et al and Enye et al which reported a body weight loss in doses of 25 mg/kg and 80 mg/kg of carbamazepine respectively^{14,15}. The pathophysiology behind this weight loss is not completely understood but studies pointed out the negative influence of carbamazepine on the hypothalamic feeding center¹⁴. Our study also demonstrates insignificant improvement in weight with the addition of Vit E to CBZ. This improvement has also been shown in a study that used 100 mg/kg of vitamin E to significantly ameliorate the decrease in body weight secondary to cadmium toxicity¹⁶. Another study reported partial improvement with Vit E in acrylamide-induced weight loss¹⁷.

The difference in absolute or relative organ weight is an indication of the chemical toxicity of that organ¹⁸. Our study demonstrates a decrease in both absolute and relative splenic weight in carbamazepine-treated rats. In contrast, Kwast et al reported no change in splenic weight in rats consuming carbamazepine at a dose of 100 mg/kg each day¹⁹. Vit E acting as a protective agent, increased the splenic weight near to the control Group I. This was also seen with a study in which Vit E was able to alleviate Diethylhexyl Phthalate-induced splenic weight reduction²⁰. Selected hematological parameters showed an insignificant decrease in the hemoglobin of Group II (carbamazepine-treated). The study of Zita et al. showed a similar decrease in hemoglobin levels following low as well as high doses of carbamazepine⁹.

The White blood cells (WBCs) regulate the body's immunity. Alterations in the total leucocyte count in the CBZ-treated Group II showed an insignificant increase which is supported by the study of Akorede et al. but is opposite to the observations of Zita et al.^{9,21}. This observed leukocytosis can result from significant neutrophilia, i.e., increased neutrophil count, also seen in our study, secondary to stimulation of the immune system, which is supported by the study of Rezaei et al²². There is a significant decrease in lymphocytes in the CBZ-treated Group II which is the same in the study by Akorede et al²¹.

Our study showed thrombocytopenia, i.e., decreased platelet count, in the CBZ group, which is supported by prior reports²³. The study demonstrated the platelets underwent apoptosis after CBZ treatment through protein kinase A while another contradictory report showed thrombocytosis²¹. Concurrent treatment with Vit E was shown to increase the platelet count due to its protective effects on the hematopoietic system as also shown in another study²⁴.

Splenic toxicity, secondary to CBZ intake was demon-

strated in the H & E-stained tissue. The white pulp was reduced, and the marginal zone was less distinct. Vacuoles were observed in the wall of the central artery. A study done by Tamura demonstrated visible germinal center hyperplasia after CBZ ingestion, as the only change in splenic pulp²⁵. In another study observing splenic toxicity, secondary to cyclosporin dosing, the white pulp was reduced, the red pulp was congested, and the central artery's endothelial layer showed vacuoles²⁶. Damaging effects on the spleen are evident in literature from other agents as well, like copper sulfate and silver nanoparticles, which have shown depletion of white pulp and congestion of red pulp^{11,27}.

Concurrent treatment of the rats of Group III with Vit E and CBZ showed a reversal of the toxic effects of CBZ to almost normal histologic architecture of the spleen. This ameliorative potential of Vit E agrees with findings in previous research that studied copper and flubendamide-induced splenic injury¹¹. Comparable antioxidative effects of Vit E against Titanium dioxide nanoparticles on splenic toxicity have also been observed in a study²⁸.

The strength of this study is that it is the second only of its kind to determine the histoarchitectural changes of the spleen induced by CBZ, a commonly prescribed antiepileptic. The limitation of our study was that immunohistochemistry staining could have been performed to ascertain the effect of CBZ on different lymphocyte populations within the splenic pulp. The study could further be carried out in the human population and the antioxidative potential of Vit E on the hematological parameters could be determined.

CONCLUSION

This study demonstrated the ameliorative effect of Vit E against CBZ-induced splenotoxicity in a rat model. Simultaneous administration of Vit E with CBZ, decreased splenic insults as seen through histomorphology and hematological parameters. These effects are accounted for because of the antioxidative properties of Vit E. Vit E introduction as a lone agent showed supplemental effects and improved normal parameters. This experimental study implies that Vit E may assist as an adjuvant therapy to mitigate oxidative injury secondary to CBZ in clinical practice, due to which it is frequently discontinued.

ACKNOWLEDGEMENTS

None.

CONFLICT OF INTEREST

The authors declared no conflict of interest.

ETHICAL APPROVAL

Ethical approval was taken from the ERC of Sohail University, protocol no: 000028/20.

AUTHORS CONTRIBUTIONS

ABA: conceptualized the study, formulated the research plan, dissected the animals, and manuscript writing. NY: animal care and dissection; histological examination and manuscript writing. SM: supervision, data interpretation, and manuscript review. LF: drafted and revised the manuscript, and data interpretation. TK: data acquisition through tissue preparation, staining, and manuscript writing. AA: critical analysis and manuscript writing.

REFERENCES

1. Rashad E, Hussein S, Bashir DW, Ahmed ZO, El-Haback H. Anatomical, histological, histochemical, scanning and transmission electron microscopic studies on water Buffalo (Bubalus Bubalis) Spleen. *J Crit Rev.* 2020;7(17):6154-6173.
2. Dumas L, Roussel C, Buffet P. Intra-erythrocytic vacuoles in asplenic patients: elusive genesis and original clearance of unique organelles. *Front Physiol.* 2023;14:1324463. <https://doi.org/10.3389/fphys.2023.1324463>
3. Kashimura M. The human spleen is the center of the blood defense system. *Int J Hematol.* 2020;112(2):147-158. <https://doi.org/10.1007/s12185-020-02912-y>
4. Wang X, Yan X, Yang Y, Yang W, Zhang Y, Wang J, Ye D, Wu Y, Ma P, Yan B. Dibutyl phthalate-mediated oxidative stress induces splenic injury in mice and the attenuating effects of vitamin E and curcumin. *Food Chem Toxicol.* 2020;136:110955. <https://doi.org/10.1016/j.fct.2019.110955>
5. García-Medina S, Galar-Martínez M, Gómez-Oliván LM, del Consuelo Torres-Bezaury RM, Islas-Flores H, Gasca-Pérez E. The relationship between cyto-genotoxic damage and oxidative stress produced by emerging pollutants on a bioindicator organism (*Allium cepa*): the carbamazepine case. *Chemosphere.* 2020;253:126675. <https://doi.org/10.1016/j.chemosphere.2020.126675>
6. Akorede GJ, Ambali SF, Olatunji AO, Shittu M, Aremu A, Basiru A, et al. Protective effect of vitamin C on chronic carbamazepine-induced reproductive toxicity in male wistar rats. *Toxicol Rep.* 2020;7:269-276. <https://doi.org/10.1016/j.toxrep.2020.01.017>
7. Chen RJ, Ershad M, Dela Cruz M, Mostafa AM. Carbamazepine toxicity masquerading as complex febrile seizures in a pediatric patient. *Case Rep Emerg Med.* 2020;2020. <https://doi.org/10.1155/2020/1790310>
8. Beydoun A, DuPont S, Zhou D, Matta M, Nagire V, Lagae L. Current role of carbamazepine and oxcarbazepine in the management of epilepsy. *Seizure.* 2020;83:251-263. <https://doi.org/10.1016/j.seizure.2020.10.018>
9. Zita L, Kurhan S, Krunt O, Chmeliková E, Kraus A, Čítek J, et al. The Effect of Carbamazepine on Performance, Carcass Value, Hematological and Biochemical Blood Parameters, and Detection of Carbamazepine and Its Metabolites in Tissues, Internal Organs, and Body Fluids in Growing Rabbits. *Anim.* 2023;13(12):2041. <https://doi.org/10.3390/ani13122041>
10. Blaner WS, Shmarakov IO, Traber MG. Vitamin A and vitamin E: will the real antioxidant please stand up?. *Annu Rev Nutr.* 2021;41:105-131. <https://doi.org/10.1146/annurev-nutr-082018-124228>
11. Mandil R, Prakash A, Rahal A, Singh SP, Sharma D, Kumar R, et al. In vitro and in vivo effects of flubendamide and copper on cyto-genotoxicity, oxidative stress and spleen histology of rats and its modulation by resveratrol, catechin, curcumin and α -tocopherol. *BMC Pharmacol Toxicol.* 2020;21:1-7. <https://doi.org/10.1186/s40360-020-00405-6>
12. Andrade-Mena CE. Immunodepression induced by carbamazepine administration is mediated by CD 8+ spleen T cells. *Int J Tissue React.* 1996;18(2-3):81-85.
13. Pacific R, Di Carlo S, Bacosi A, Pichini S, Zuccaro P. Immunomodulating properties of carbamazepine in mice. *Int J Immunopharmacol.* 1992;14(4):605-611. [https://doi.org/10.1016/0192-0561\(92\)90121-Z](https://doi.org/10.1016/0192-0561(92)90121-Z)
14. Osuntokun OS, Babatunde AA, Olayiwola G, Atere TG, Oladokun OO, Adedokun KI. Assessment of the biomarkers of hepatotoxicity following carbamazepine, levetiracetam, and carbamazepine-levetiracetam adjunctive treatment in male Wistar rats. *Toxicol Rep.* 2021;8:592-598. <https://doi.org/10.1016/j.toxrep.2021.03.008>
15. Enye LA, Saka OS, Adekanye UA, Adekeye AO, Abijo AZ, Ige MS. Hippocampal Histomorphology and Biochemistry in Rats fed Diets containing Carbamazepine. *Afr J Biomed Res.* 2022;25(1):89-94.
16. Fang J, Yin H, Yang Z, Tan M, Wang F, Chen K et al. Vitamin E protects against cadmium-induced sub-chronic liver injury associated with the inhibition of oxidative stress and activation of Nrf2 pathway. *Ecotoxicol Environ Saf.* 2021;208:111610. <https://doi.org/10.1016/j.ecoenv.2020.111610>
17. Üremiş MM, Gültekin S, Üremiş N, Şafak T, Çiğremiş Y, Gül M, et al. Protective role of vitamin E against acrylamide-induced testicular toxicity from pregnancy to adulthood: insights into oxidative stress and aromatase regulation. *Naunyn Schmiedebergs Arch Pharmacol.* 2024;397(2):829-841. <https://doi.org/10.1007/s00210-023-02638-8>
18. Kharchoufa L, Bouhrim M, Bencheikh N, El Assri S, Amirou A, Yamani A, et al. Acute and subacute toxicity studies of the aqueous extract from *Haloxylon scoparium* Pomel (*Hammada scoparia* (Pomel)) by oral administration in rodents. *BioMed Res Int.* 2020;2020:4020647. <https://doi.org/10.1155/2020/4020647>
19. Kwast L, Fiechter D, Kruijssen L, Bleumink R, Ludwig I, Bol-Schoenmakers M, et al. Oral exposure to immunostimulating drugs results in early changes in innate immune parameters in the spleen. *J Immunotoxicol.* 2016;13(4):535-547. <https://doi.org/10.3109/1547691X.2016.1139643>
20. Akinwumi KA. Vitamin E Alleviates Diethylhexyl Phthalate-Induced Haematological Changes and Splenic Oxidative Injury in Male Sprague-Dawley Rats.

- J Can Res Updates. 2019;8(1):42-51.<https://doi.org/10.30683/1929-2279.2019.08.06>
21. Akorede GJ, Ambali SF, Olatunji AO, Aremu A, Ahmed AO, Basiru A, et al. Vitamin C Protects Against Blood and Thyroid Toxicities Induced by the Chronic Use of Carbamazepine in Rats. *Iran J Toxicol*. 2023;17(2):147-156. <http://dx.doi.org/10.32598/IJT.17.2.1080.1>
22. Rezaei M, Mashinchian Moradi A, Mortazavi P, Jamili S. Effects of chronic exposure to carbamazepine on hematological parameters in *Cyprinus carpio*. *Iran J Fish Sci*. 2020;19(1):443-456. <https://doi.org/10.22092/IJFS.2019.119014>
23. Xiao W, Zhou K, Yang M, Sun C, Dai L, Gu J, et al. Carbamazepine induces platelet apoptosis and thrombocytopenia through protein kinase A. *Front Pharmacol*. 2021;12:749930. <https://doi.org/10.3389/fphar.2021.749930>
24. Eid FA, El-Gendy M, Zahkook SA, El-Tahway NA, El-Shamy S. Ameliorative effect of two antioxidants on the liver of male albino rats exposed to electromagnetic field. *Egypt J Hosp Med*. 2015;58(1):74-93.<https://doi.org/10.12816/0009363>
25. Tamura A, Miyawaki I, Yamada T, Kimura J, Funabashi H. Oral administration of drugs with hypersensitivity potential induces germinal center hyperplasia in secondary lymphoid organ/tissue in Brown Norway rats, and this histological lesion is a promising candidate as a predictive biomarker for drug hypersensitivity occurrence in humans. *Toxicol Appl Pharmacol*. 2013;271(1):30-40. doi: 10.1016/j.taap.2013.04.022.
26. Younus N, Sultana K, Ali AB. The Toxic Effects of Cyclosporine on Splenic Tissue of Rat and it's Amelioration with *Nigella Sativa*. *Int J Pathol*. 2017; 15(2):44-50.
27. Mazen NF, Saleh EZ, Mahmoud AA, Shaalan AA. Histological and immunohistochemical study on the potential toxicity of silver nanoparticles on the structure of the spleen in adult male albino rats. *Egypt J Histol*. 2017;40(3):374-387. doi: 10.21608/EJH.2017.4662
28. Afshari-Kaveh M, Abbasalipourkabir R, Nourian A, Ziamajidi N. The protective effects of vitamins A and E on titanium dioxide nanoparticles (nTiO₂)-induced oxidative stress in the spleen tissues of male Wistar rats. *Biol Trace Elem Res*. 2021;199:3677-3687. <https://doi.org/10.1007/s12011-020-02487-z>
-