

CASE REPORT

URINOTHORAX PRESENTING AS RESPIRATORY DISTRESS AFTER NEPHROLITHOTOMY

Syed Mahmood ul Haq, Imroz Arif Farhan, Jawed Ahmed Memon, Mariya Muhammad Salim
Thoracic Surgery Department, Liaquat National Hospital and Medical College, Karachi.

ABSTRACT

Urinothorax is a rare complication of thoracic cavity often arising secondary to genitourinary pathology of which the most common is urinary tract obstruction. If urine is accumulated in the pleural space, it is termed as Urinothorax. Here we are reporting two cases presenting with right renal flank pain that underwent Percutaneous Nephrolithotomy and subsequent Double J (DJ) stenting due to right renal calculi. These patients then developed shortness of breath secondary to pleural effusion. At first, they were thought to be suffering from pulmonary embolism and their electrocardiography (ECG) and Chest X-rays were done. ECG showed no acute changes hence further investigations were done. Imaging and biochemical investigations aided in confirmation of the diagnosis of Urinothorax. Treatment of this condition is dependent upon a multidisciplinary approach aiming towards resolution of the underlying cause of this pathology. In this case, report we would like to briefly discuss our experience of management and clinical outcomes of Urinothorax at a tertiary care institute.

Keywords: Urinothorax; Pleural Effusion; Surgery.

Corresponding Author:

Dr. Imroz Arif Farhan

Thoracic Surgery Department, 2nd floor Block-K,
Liaquat National Hospital and Medical College,
Stadium Road, Karachi, Pakistan.
Email: miaf942@yahoo.com

INTRODUCTION

Urinothorax is a sparse form of pleural effusion, which occurs due to leakage of urine into the retroperitoneal cavity. The urine then seeps up in the pleural space via anatomic diaphragmatic defect or via lymphatic channel¹. Etiology can be either obstructive or traumatic/iatrogenic. Common iatrogenic injuries include procedures such as PCNL (Percutaneous Nephrolithotomy) and Ureteroscopy². Management involves thoracentesis with pleural fluid analysis, which comes out to be transudative in accordance of Light's Criteria with elevated Lactate Dehydrogenase and a ratio of fluid creatinine to serum creatinine more than 1.09. Here we are reporting 2 cases of Urinothorax secondary to PCNL performed due to renal stones.

CASE 1:

34 years old female, married with no known co-morbidities, was admitted through urology outpatient department, with complaints of Right flank pain for 1 year. CT pyelogram was performed which showed a 2.6cm calculi in right renal pelvis. She had an Elective Right Percutaneous Nephrolithotomy +

Right DJ stenting. On 2nd post-op day her Nephrostomy tube was clamped and Chest X-ray was performed which was normal. On 3rd post-op day her Nephrostomy tube was removed. On fourth post-operative day, she had severe difficulty in breathing and CXR showed right sided opaque hemithorax suggestive of Right sided large pleural effusion (Figure A) for which Right tube thoracostomy was performed. Chest drain output was 3 Liters of straw-colored pleural effusion. In view of the history of Percutaneous Nephrolithotomy, the fluid was sent for biochemical analysis, which showed fluid creatinine levels of 7.5mgs/dl. Serum creatinine was 0.8mgs/dl and the pleural fluid creatinine ratio to serum creatinine came out to be 9.37, which confirmed Urinothorax. Foleys catheter was passed, this reduced chest drain output markedly and lung expanded fully. Patient was mobilized and discharged home on 7th postoperative day with chest tube in-situ and a urinary catheter. She was on regular Outpatient Department follow-ups. The urinary catheter was removed 7 days after discharge. Meanwhile her drain output was monitored. The chest drain was removed 10 days after discharge as there was no drainage and CXR showed no residual pleural effusion (Figure B).

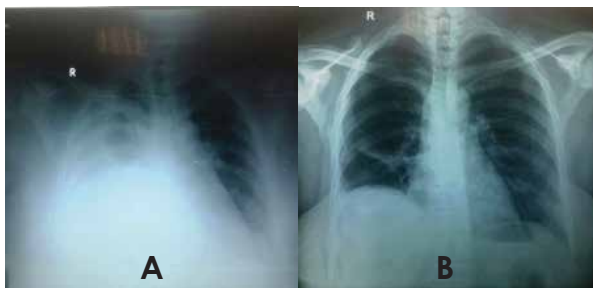


Figure A: Chest X-ray 4th postoperative Day (after removal of Nephrostomy) showing right hydrothorax, Figure B: Chest X-ray on 10th postoperative day showing no residual intrapleural collection.

CASE 2:

19 years old male, un-married with no known co-morbidities, was admitted through urology outpatient department, with complaints of right flank pain for 1 week. He had a previous history of Lithotripsy for left renal stone 1 year ago. Current CT pyelogram showed 2.8cm right pelvi-ureteric junction stone and 0.7cm left mid pole renal stone. Elective Right Percutaneous Nephrolithotomy + Left Ureteroscopy + Left DJ stenting was performed.

On first Post-operative day patient complained of pain in right sub-costal region along with difficult breathing. His CXR had opacity in Right lung field (hemithorax) suggestive of right sided large pleural effusion (Figure C); a right tube thoracostomy was performed. Drain output was 1.8liters of straw colored pleural fluid. In view of history of Percutaneous Nephrolithotomy procedure, pleural fluid was sent for pleural fluid creatinine levels, which came out to be 12.5mg/dl, Serum creatinine was 1.74mgs/dl, and the pleural fluid creatinine ratio to serum creatinine came out to be 7.18, which confirmed Urinothorax. Patient was released for home on 5th postoperative day with chest tube in-situ and urinary catheter. He was reviewed in Outpatient Department. His urinary catheter removal was done on 6th follow up day. Meanwhile the drain output was monitored. The chest drain was removed 12 days after discharge, as there was no drain output; following removal of urinary catheter and the chest x-ray performed showed a well-expanded lung (Figure D).

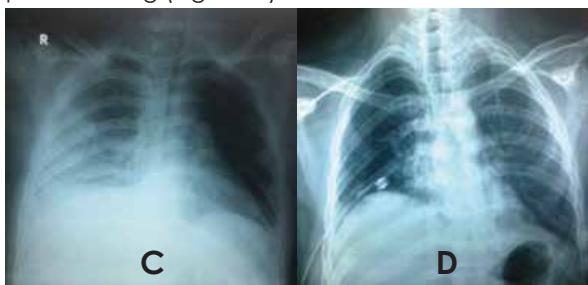


Figure C: Chest X-ray 11th postoperative day (after removal of Nephrostomy) showing right hydrothorax, Figure D: Chest X-ray on 10th postoperative day showing no residual intrapleural collection.

Figure D: Chest X-ray on 10th postoperative day showing no residual intrapleural collection.

Currently not much literature is available on Urinothorax other than a few case reports that range from 1-2 cases. Because of this, major characteristics and effective treatment modalities are not well known². Urinothorax is an uncommon etiology of transudative pleural effusion. Various theories exist regarding formation of Urinothorax that can be broadly classified into two categories. Firstly Urinothorax as a consequence of a urinoma formation in the retroperitoneum secondary to any obstruction in the urinary tract or an extravasation due to discontinuation of urinary tract as a traumatic consequence³. This retroperitoneal urinary collection subsequently travels up into the pleural space through a defect in diaphragm or via lymphatic channel. The reason for upward movement of urine into the pleural space is unknown. However, one assumption is that this is due to negative pressure in the pleural cavity. Secondly, Urinothorax can occur when simultaneously injury (iatrogenic or traumatic) to urinary tract and the pleural cavity can result in fistulous direct communication between the two.

Diagnostic criteria include a transudative pleural effusion with elevated LDH and a ratio of fluid creatinine to serum creatinine exceeding 1.094. Urinothorax should be suspected in all patients that develop pleural effusion secondary to any gynecological or urological surgical procedures⁵. In our cases we found classical parameters for Urinothorax which include a history of urological surgical procedure, massive straw colored pleural effusion and highly elevated fluid to serum creatinine ratio⁶ whereas average pleural fluid to serum creatinine ratio is 1.09-19.80^{7,8}. Higher degree clinical suspicion is needed for Urinothorax diagnosis⁹. Other diagnostic modalities include use of v99mTc DTPA and SPECT-CT scans¹⁰. In our cases since being part of developing country and affordability issues of patients these radiological options were not considered and diagnosis were only done on the basis of x-rays and biochemical parameters. At present, no well-defined treatment guidelines are available for the treatment of Urinothorax. In our cases, we opted for a multidisciplinary approach where tube thoracostomy was done and the cases were managed with routine chest x rays and biochemical investigations in collaboration with the urology department. Foleys catheter was removed post operatively before removal of thoracotomy tube. The patient was then observed and managed conservatively till the patient was subjectively better with no signs and symptoms of pleural effusion along with clearance of residual pleural effusion confirmed on chest x-rays. Early diagnosis and treatment should be emphasized for Urinothorax reason being due to existence of urine in pleural space there is a high chance of developing primary pleural infections or secondary pleural infections

due to communication developed between the renal outflow channel and the pleural space that may complicate the clinical management of Urinothorax.

CONCLUSION

In conclusion, a higher emphasis on clinical suspicion would help in diagnosis and treatment of Urinothorax especially in cases of patients developing shortness of breath secondary to gynecological or urological procedure. We believe that in our cases the Percutaneous Nephrolithotomy caused puncture of pleural cavity. However, it is our opinion that the Urinothorax only occurred when urinary catheter was removed prematurely before the closing of the tract formed between the pleural cavity and renal drainage system.

ACKNOWLEDGMENTS

We would like to acknowledge all the patients who consented to provide their cases for the study.

CONFLICT OF INTEREST

The authors declare no conflict of interest.

AUTHORS CONTRIBUTION

All authors equally contributed to this study.

REFERENCES

1. Kelley M, Spieler B, Rouse C, Karl B, Marshall R, Carbonella G. Urinothorax: A rare complication of percutaneous nephrostomy. *Radiol Case Rep.* 2019;14(6):729-33.
2. Toubes ME, Lama A, Ferreiro L, Golpe A, Álvarez-Dobaño JM, González-Barcala FJ, et al. Urinothorax: A systematic review. *J Thorac Dis.* 2017;9(5):1209-18.
3. Puthenveedu DK, Manickam N, Subramanian AR, Baluchamy PK. Urinothorax: a rare postoperative complication of adrenalectomy. *JCDR.* 2016;10(5):OD11.
4. Waqas M, Nawaz G, Raja A, Hussain I. Urinothorax in a child secondary to obstructive renal stone in a solitary functioning kidney : a case report. *CEN Case Rep.* 2016;5(2):209-11.
5. Chandra A, Pathak A, Kapur A, Russia N, Bhasin N. Urinothorax: A rare cause of severe respiratory distress. *Indian J Crit Care Med.* 2014;18(5):320.
6. Casallas A, Castaneda-Cardona C, Rosselli D. Urinothorax: Case report and systematic review of the literature. *Urol Ann.* 2016;8(1):91.
7. Laskaridis L, Kampantais S, Toutziaris C, Chachopoulos B, Perdakis I, Tahmatzopoulos A, et al. Urinothorax—An Underdiagnosed Cause of Acute Dyspnea: Report of a Bilateral and of an Ipsilateral Urinothorax Case. *Case Rep Emerg Med.* 2012;2012:1-3.
8. Garcia Pachon E, Padilla Navas I. Urinothorax: Case report and review of the literature with emphasis on biochemical diagnosis. *Respiration.* 2004;71:533-6.
9. Jabbour Y, Lamzaf Y, Karmouni T, El Khader K, Koutani A, Andaloussi Al. Dyspnea Revealing an Uncommon Complication of Kidney Obstruction: Urinothorax. *Eurasian J Med.* 2018;50(3):213.
10. Lee TW, Jang HN, Cho HS, Choi SM, Choi BH, Bae E, Chang SH, Park DJ. Urinothorax after ultrasonography-guided renal biopsy: a case report. *BMC Nephrol.* 2018;19 (1):104.